

## **Trichoscopy of pemphigus vulgaris in remission. A tool for treatment-cessation decision making? Preliminary results**

DOI: 10.46981/sfjvh3n3-003

Received in: April 29<sup>th</sup>, 2022

Accepted in: June 30<sup>th</sup>, 2022

### **Ioannis Sidiropoulos**

MD Dermatology - Venereology

Institution: "Ippokrateion" Hospital, Department for Skin Diseases, Thessaloniki - Greece

Address: 124, Delphi Str, 54643, Thessaloniki - Greece

E-mail: tsidiropoulos@hotmail.com

### **Georgios Ch. Chaidemenos**

PhD in Dermatology-Venereology

Institution: "Dimocriteion" University, Alexandroupolis, Thrace - Greece

Address: Private Office: 6 Kosma Aitolou, 54642 Thessaloniki - Greece

E-mail: cgiorgos@otenet.gr

### **ABSTRACT**

**Background** One of the controversies in the treatment of Pemphigus Vulgaris (PV), is the time of treatment cessation. Scalp involvement is often the most stubborn to treatment body site and may reflect disease activity. Trichoscopy (Dermoscopy of scalp) features have not been studied in clinically "healthy-looking" skin of patients in full remission. **Aims and Objectives** To find out if there are any trichoscopy features in PV patients in clinical and immunologic remission, and accommodate treatment decision **Methods** The age and disease duration of 3 women with PV were correspondingly 62, 63, 55 and 5, 6, 15 years. Treatment at examination was 2,5 mg prednisone(Pr), for the last 22, 5 and 7 months. The 2nd patient was also taking 1 mg/kg/d of Azathioprine. Anti Desmoglein antibodies turned to negative since Oct/2017, Feb/2017, Sept/2015. Contact dermoscopy and hand lens X10 magnifier for clinical evaluation, were used. **Results** A red hue background, peripillar scales and tubular casts were observed by trichoscopy in the first 2 patients. Only peripilar scales on a small brown round area were the features in the 3rd patient. Treatment cessation was decided only in this patient, since casts observed in the other two patients, were considered as a consequence of outer root sheath acantholysis and a sign of disease activity **Conclusions** Areas of red hue skin background and movable cylindrical scales (casts) around hair shafts may be observed, even in the absence of apparent scalp clinical involvement, in PV patients in remission. Since these features may drive physicians to treatment continuation, dermoscopy of the scalp is required in clinically "healthy-looking" PV patients, before a decision of treatment cessation is made. Future studies with greater number of patients, furtherly validated by long term disease course outcome, are needed

**Keywords:** trichoscopy, dermoscopy, pemphigus vulgaris, treatment, remission

### **1 INTRODUCTION**

Pemphigus Vulgaris (PV) is a rare, potentially fatal autoimmune vesiculo-bullous disease of mucous membranes and/or skin, that is induced by the loss of keratinocyte adhesion because of the

production of antibodies against desmoglein-3(Dsg-3), as the main autoantigen and in half of cases, against Desmoglein-1(Dsg-1)<sup>(1)</sup>. Following disease suppression, mainly with systemic corticosteroids, a realistic goal is treatment withdrawal, a procedure that should be cautious because of high relapse rates if done prematurely.<sup>2</sup>

Treatment-cessation main prerequisites are the clinical and immunologic remission of PV. The latter is defined as the absence of circulating anti-Dsg serum antibodies, the absence of Malpighian layer intercellular antibodies from the “healthy-looking” skin with Direct Immune-fluorescence (DIF)<sup>(3)</sup>, and in case of scalp involvement a negative hair-DIF result of plucked anagen hairs<sup>(4)</sup>. However, these procedures are time and money consuming, require technical equipment, a surgical biopsy and most of all, are not invariably correct in disease course prediction.

Scalp involvement in PV is associated with the abundance of desmogleins localized in hair follicles but not necessarily with disease severity<sup>(5)</sup>. Trichoscopy (dermoscopy of hair and scalp) features of active PV have been adequately documented<sup>(6)</sup>. Although a sub-macroscopic skin evaluation is achieved with this non-invasive, “in vivo” procedure, no study of the mildly involved or even “healthy-looking” skin of scalp Pemphigus in remission, is known. This study was structured to find out if there are any trichoscopy features in PV patients in clinical and immunologic remission, so that an accommodate treatment decision would be undertaken

## 2 METHODS AND RESULTS

Three women suffering from PV in remission, i.e. without obvious clinical signs and no anti-Dsg antibodies, were evaluated by contact non-polarized dermoscopy on diverse areas of their scalp under the aid of Videodermoscopy with a X10 fold working standard magnification. Hand lens with X10 magnifier, was used for clinical evaluation. Initial clinical diagnosis was confirmed by histology, DIF of perilesional skin and circulating anti-intercellular and anti-Dsg antibodies. Clinical and Immunologic remission were considered as the absence of any lesions and no detection of circulating anti-Dsg antibodies, correspondingly. Treatment with oral Prednisone and a 2<sup>nd</sup> immunosuppressant followed the steps explained in previous article<sup>(7)</sup>. The main parameters of the disease course in our patients are shown in Table 1. Anti Dsg 3 antibodies were initially present in all cases. Anti-Dsg 1 antibodies were also positive (title cut-off >20) in patients 2 and 3. Hairs in the areas of PV involvement were in the anagen phase. Pull test was negative in all cases. Tzank’s smear test for acantholysis was also nonproductive

Trichoscopy findings are described in Table I. Despite the absence of any clinical sign of disease, except a sensation of pruritus in patients 2 and 3, erythema was a dermoscopic feature in two patients (1,2). Especially in patient Nr 1, erythema was attributed, with the aid of larger magnifications, to large

non-focus vessels around hair follicles. Peri-pilar scales was a constant, though variable in intensity, sign. Tubular casts were observed only in the first patient, and this was a decisive feature for this patient’s treatment continuation.

“Starburst” hyperplasia was observed in patients 1. This feature did not influence our treatment decision making, for the time being

Table I. Features of 3 patients with PV in “remission”

<b>Patients</b> Sex, age/ disease duration	<b>Involvement</b> in order of appearance	<b>Previous Treatment</b>	<b>Current Therapy.</b> (As of Dec 2019). Tx Since	<b>Duration of remission,</b> clinical / Immunologic	<b>Present Dermoscopy</b> (As of Dec 2019)
<b>Nr 1.</b> F, 62 / 5 Yrs	Scalp, Trunk, legs, Oral and Urethral Mucosae	<u>10/2015</u> : PRD 1 to 1.5 mg/kg/d <u>9/2016</u> : RTX, 2 cycles	<u>2/2018</u> : PRD 5 mg /2 <sup>nd</sup> D	22 mo / 26 mo	Non-focus, large vessels around hair orifices, giving a red-hue appearance; several peripilar casts, even outside the red skin area; collar-like scaling in some hairs; peripilar “starburst” sign
<b>Nr 2.</b> F, 63 / 5 Yrs	Scalp, Trunk, legs, Nasal mucosa	<u>10.2015</u> : PRD 1mg/kg /d <u>1.2016</u> : +AZA 1,5 mg/kg/d <u>4/2019</u> : PRD 30mg/d	<u>6.2019</u> : PRD 5 mg/2 <sup>nd</sup> D +AZA 0.8 mg/kg/D	6 mo / 34 mo	On a slightly red background, hairs with minor perifollicular scaling; well circumscribed dull-red dots, involving 2-3 hair orifices possibly corresponding to regressed pustules.
<b>Nr 3.</b> F, 55 / 15 yrs	Scalp, Trunk, Oral mucosa	<u>6.2014</u> : PRD 40 mg/2 <sup>nd</sup> D +AZA 100 mg/D	<u>2.2017</u> : PRD 5 mg/2 <sup>nd</sup> D	7 mo / 53 mo	On a small light-brown area, silver-white scales entangling hairs up to few millimeters above scalp surface.

AZA: Azathioprine, D: Day, F: Feminine, mo: months, Nr: Number, PRD: Oral Prednisone, RTX: Rituximab, Tx:Treatment, Yrs: Years. +: Plus

Fig.1. Patient, Nr 1. Non-polarized contact dermoscopy: Large non-focus vessels giving a red-hue appearance. Peripilar, tubular casts. ‘Starburst sign’ at the center of lesion (original magnification x10)

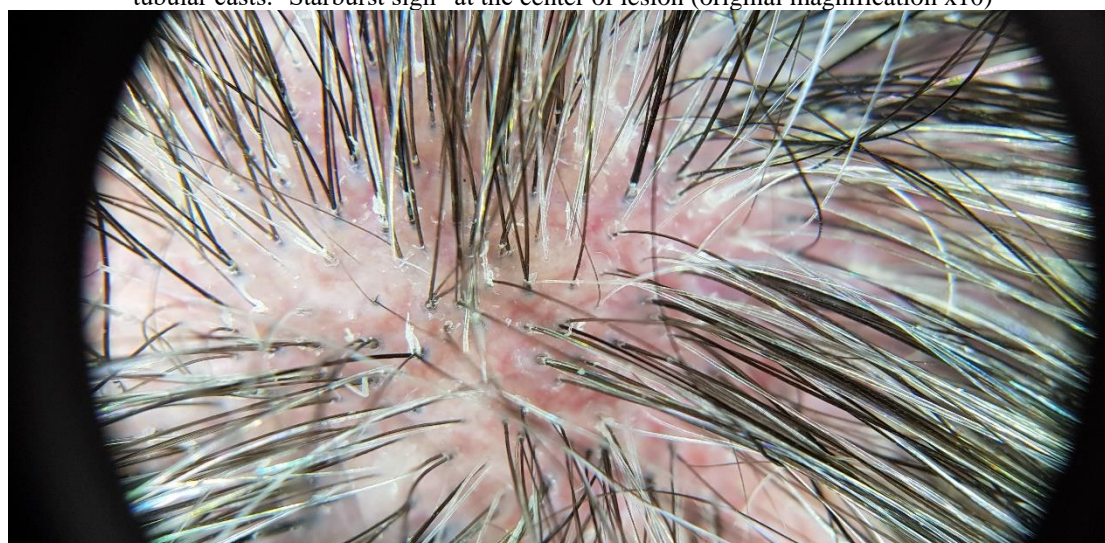



Fig.2 Patient, Nr 2. Non-polarized contact dermoscopy: Minor perifollicular scaling involving many hairs on a slightly red background (original magnification x10)

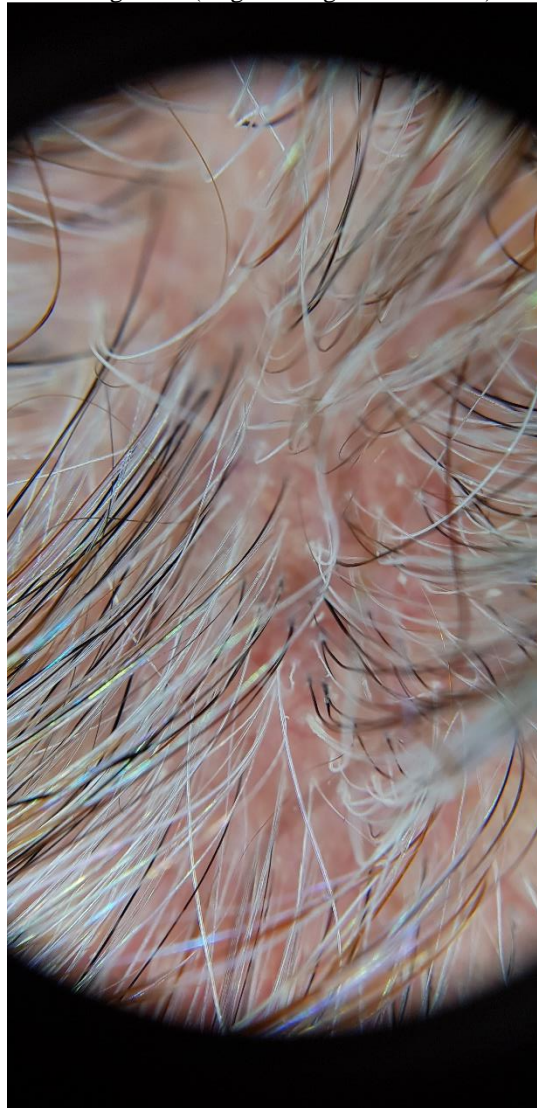


Fig 3. Patient Nr 3. Non-polarized contact dermoscopy: Silver-white scales entangling hairs up to few millimeters on a small round light brown area. (original magnification x10)

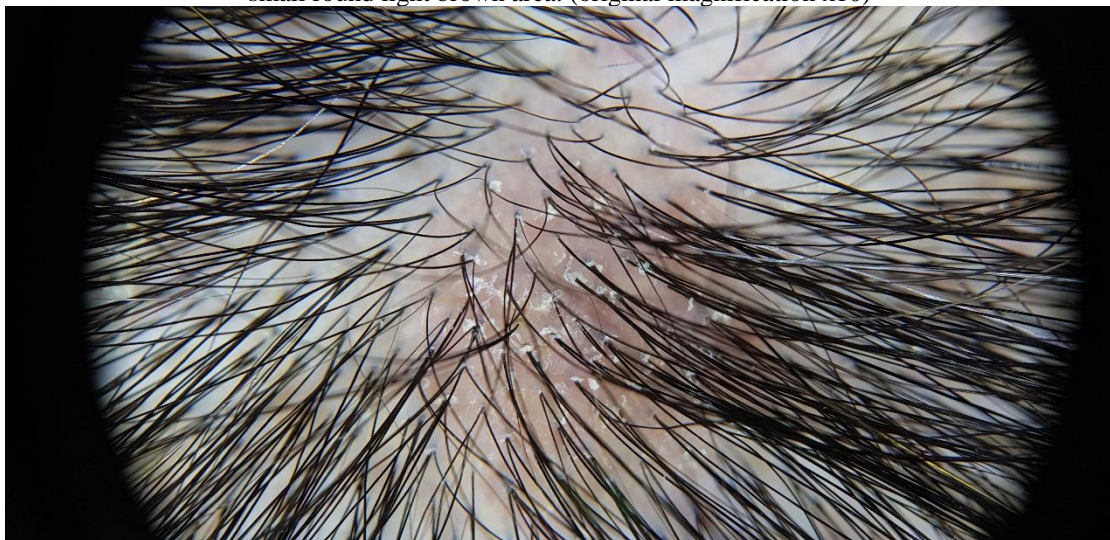
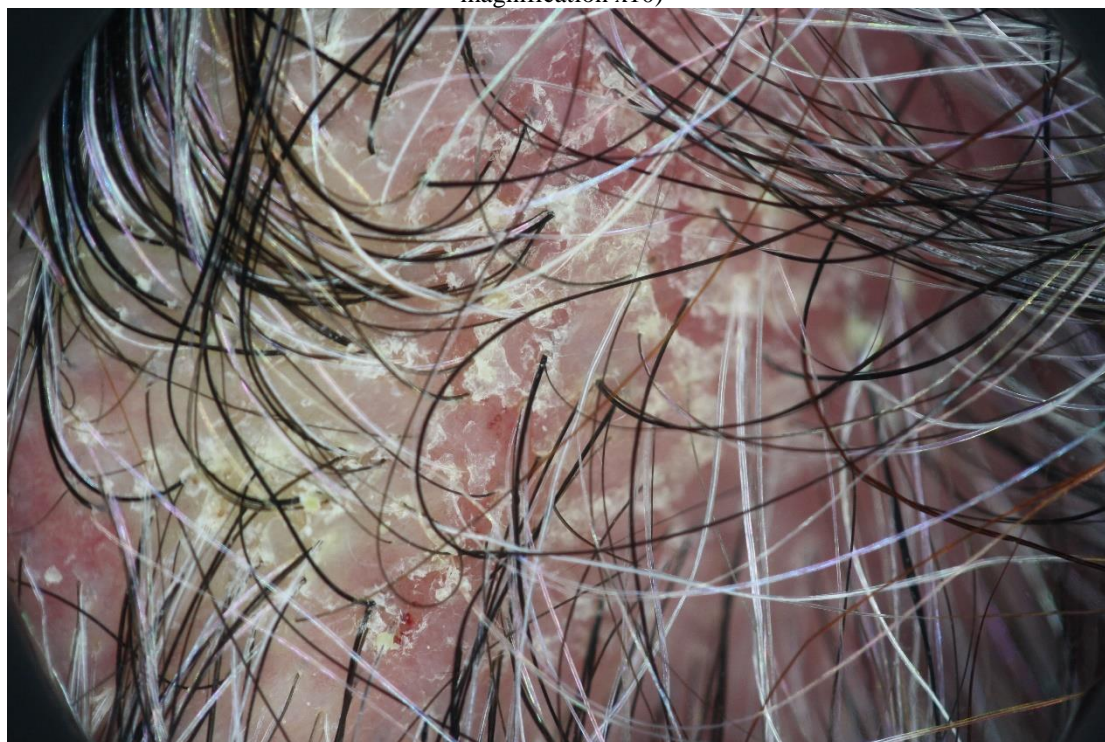
Fig 4. Patient Nr 2. Non-polarized contact dermoscopy: Dermoscopy features during active disease stage. Except from yellow crusts and erosions, glomerular and linear helical vessels are discerned at the bottom and center of figure (original magnification x10)



### 3 DISCUSSION

Scalp is estimated to involve 16-60 % of PV cases during disease course <sup>(5)</sup> and is considered as stubborn to treatment. The main features of Trichoscopy in PV have been well established <sup>(6)</sup>. Extravasations, appearing as red, hemorrhagic, polygonal structures and yellow hemorrhagic crusts, are not specific findings and occur in  $\frac{3}{4}$  of patients with PV. The co-presence of serpentine vessels, a feature seen in 77,8% of cases, may also be indicative of PV <sup>(8)</sup>. None of these features was present in our 3 patients because they entered the remission phase. They were seen in earlier active phases, where glomerular or linear helical vessels could be discerned (Fig. 4), a feature probably reflecting a more severe disease course <sup>(8)</sup>.

Hair casts are 3-7mm-long, whitish, or yellowish tubular structures which envelop the hair shafts. These movable structures were considered as indicative of ongoing acantholysis of the outer root sheath <sup>(9)</sup>. This feature combined with the red vascular background seen in our patient Nr 1 (Fig. 1), were sufficient evidence to go on with systemic therapy. Other authors include under the term of casts, the poorly defined, whitish, cotton-wool-like structures that were seen in our patient Nr 2 (Fig. 2). Since this feature is considered by the same authors as a sign of diffuse scaling <sup>(8)</sup>, we preferred to continue our treatment for this patient too, only with intralesional steroid injections. The focal, lightly brown background of the scalp in patient Nr 3 (Fig.3 ) was considered as a feature of non-active disease, since only short peri-pilar white scales without erythematous background were observed. Treatment



preference for this patient was to stop any treatment and continue only with potent topical steroids. “Starburst” hyperplasia is a frequent, though not specific feature of scarring alopecias, esp. tufted folliculitis. Their presence on the scalp of one of our patients, could be attributed to factors promoting tissue regrowth and tissue replacement since they have not been reported in active Pemphigus so far.

The consideration of our patients as immunologically inactive for PV was based only in the measurement of anti-Dsg antibodies. This serologic test is considered as good substitute for DIF in evaluating disease remission <sup>(10)</sup>. However, their usefulness in disease activity evaluation is questioned <sup>(11)</sup>. Moreover, PV patients in clinical remission without immunosuppressive therapy for 6 months, continued to present anti- DSG3 and DSG1 titers above cut-off values in 73% and 20% of cases respectively <sup>(12)</sup>.

Clinical remission ascertained with a X10 lens magnification may not be an absolute tool since two of our patients manifested focal but distinctive erythematous areas on the scalp. Following a questionnaire, these patients consented that a sensation of stinging or discomfort was present in these areas. Consequently, it is suggested that we include dermoscopy evaluation of the scalp in the clinical work-up and monitoring of PV patients. It is worthy to mention that only the extent of scalp involvement but not the structure of lesions are evaluated in the Judgement of Pemphigus Vulgaris Activity Score <sup>(5)</sup>. In consequence, our patients could not be considered as enjoying total remission. The diverse therapeutic decision followed for each of our patients, was arbitrarily based on the severity of dermoscopy features. A timely evaluation of this approach is under way.

#### **4 CONCLUSION**

Areas of red hue skin background and movable cylindrical scales (casts) around hair shafts may be observed, even in the absence of apparent scalp clinical involvement, in PV patients in remission. Since these features may drive physicians to treatment continuation, Dermoscopy of the scalp is required in clinically “healthy-looking” PV patients, before a decision of treatment cessation is made. Future studies with greater number of patients, furtherly validated by long term disease course outcome, are needed

## REFERENCES

1. Ding X., Aoki V., Mascaro J. M. Jr., Lopez-Swidorski A., Diaz L. A., and Fairley J. A. Mucosal and mucocutaneous (generalized) pemphigus vulgaris show distinct autoantibody profiles. *J Invest Dermatol* 1997;109: 592–596. doi.org/10.1111/1523-1747.ep12337524
2. Gregoriu St, Efthymiou O, Stefanaki Ch, Rigopoulos D. Management of pemphigus vulgaris: challenges and solutions. *Clin Cosmet Invest Dermatol* 2015;8: 521-527. doi:10.2147/CCID.S75908
3. Kanitakis C, Chrysomallis G, Ktenides MA, Haidemenos G. Etude en peau saine de l'immunofluorescence direct dans le pemphigus vulgaire. *Ann Dermatol Venereol (Paris)* 1978;105: 649-651
4. Daneshpazhooh M., Naraghi Z. S., Ramezani A., Ghanadan A, Esmaili N., and Chams-Davatchi C. Direct immunofluorescence of plucked hair for evaluation of immunologic remission in pemphigus vulgaris. *JAAD* 2011;65: e173-177doi: 10.1016/j.jaad.2010.09.721
5. Sar-Pomian M, Rudnicka L, Olszewska M. The significance of scalp involvement in Pemphigus: A Literature review. *Biomed Res Int Mar* 25;2018:6154397. doi: 10.1155/2018/6154397.
6. Sar-Pomian M, Rudnicka L, Olszewska M Trichoscopy – a useful tool in the preliminary differential diagnosis of autoimmune bullous diseases *IJD* 2017, 56:996-1002 doi.org/10.1111/ijd.13725
7. Mourellou O, Chaidemenos GC, Koussidou Th, Kapetis E. The treatment of pemphigus vulgaris. Experience with 48 patients seen over an 11-year period *Br J Dermatol* 1995; 133:83-87doi.org/10.1111/j.1365-2133.1995.tb02497.x
8. Sar-Pomian M., Kurzeja M., Rudnicka L., and. Olszewska M, The value of trichoscopy in the differential diagnosis of scalp lesions in pemphigus vulgaris and pemphigus foliaceus. *An Bras Dermatol* 2014; 89: 1007–1012. doi: 10.1590/abd1806-4841.20143830
9. Pirmez R. Acantholytic Hair Casts: A Dermoscopic Sign of Pemphigus Vulgaris of the Scalp. *Int J Trichol* 2012;4:172-173
10. Daneshpazhooh M, Kamyab K, Kalantari M-S, Balighi K,...and Chams-Davatchi C. Comparison of desmoglein 1 and 3 enzyme-linked immunosorbent assay and direct immunofluorescence for evaluation of immunological remission in pemphigus vulgaris. *Clin Exp Dermatol* 2014;39:41-47 doi: 10.1111/ced.12187
11. Belloni-Fortina A, Faggion D, Pigozzi B,..and Alaibak M. Detection of autoantibodies against recombinant desmoglein 1 and 3 molecules in patients with pemphigus vulgaris: correlation with disease extent at the time of diagnosis and during follow-up. *Clin Dev Immunol* 2009. Published online 2009 Dec 10. doi: 10.1155/2009/187864
- 12 Russo Ir, Paolo De Siena F, Saponeri A, Alaibac M. Evaluation of anti-desmoglein-1 and anti-desmoglein-3 autoantibody titers in pemphigus patients at the time of the initial diagnosis and after clinical remission. *Medicine (Baltimore)* 2017; 96(46):e8801. doi: 10.1097/MD.0000000000008801.